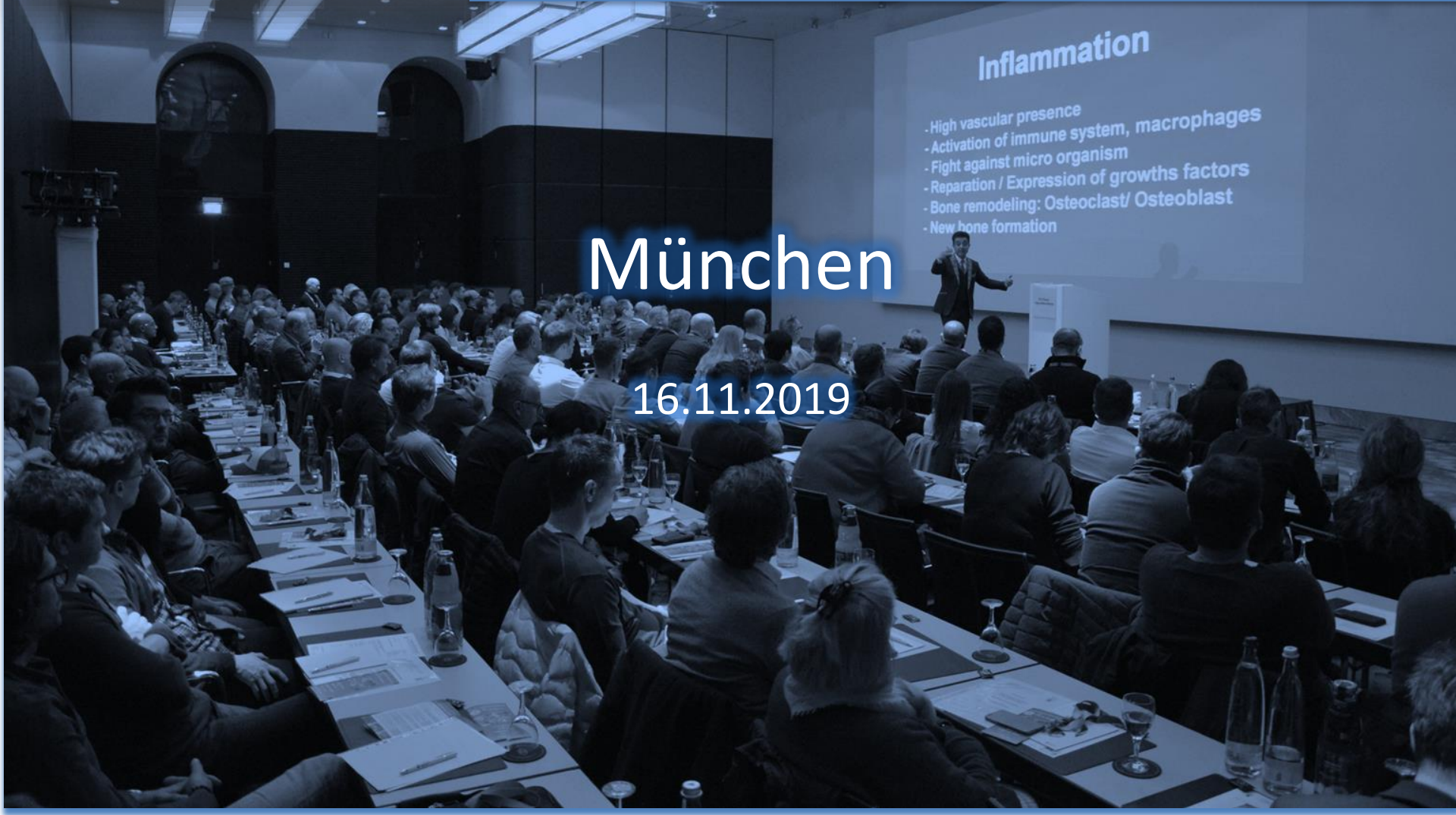



Privatzahnklinik Schloss Schellenstein

Prof. Dr. Fouad Khoury



Inflammation

- High vascular presence
- Activation of immune system, macrophages
- Fight against micro organism
- Reparation / Expression of growths factors
- Bone remodeling: Osteoclast/ Osteoblast
- New bone formation

München

16.11.2019

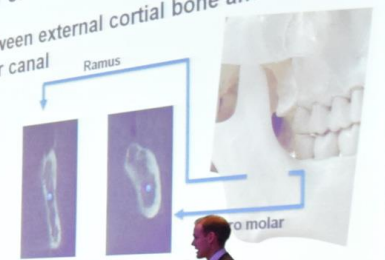


Inflammation

- High vascular presence
- Activation of immune system, macrophages
- Fight against micro organism
- Reparation / Expression of growths factors
- Bone remodeling: Osteoclast/ Osteoblast
- New bone formation

Anatomy of the retromolar region

Space between external cortical bone and mandibular canal



Dentition	2.76 ± 0.13 mm	4.9 mm
Edentulous	2.57 ± 0.32 mm	5.77 mm

LEONG, Daylene, et al. *Journal of Prosthetic Dentistry*. 2010. doi:10.1016/j.prodent.2010.05.001
GILLI, Huseyin Avni, et al. *Journal of Dentistry*. 2010.



Meisinger
since 1888



Cytoplast™





Salmon & Coleslaw
Shrimp, Crab, Avocado & Potatoes
(A, B, C, E, F, G)

Energy Bowl | Sushi Reis, Edamame,
Shim A, Kimchi, Tofu Chili, Miso Dip
(F, G, H)

French Toast | Räucherlachs,
Fruchtsäure, Avocado
(A, B, C, E, F, G, H)







